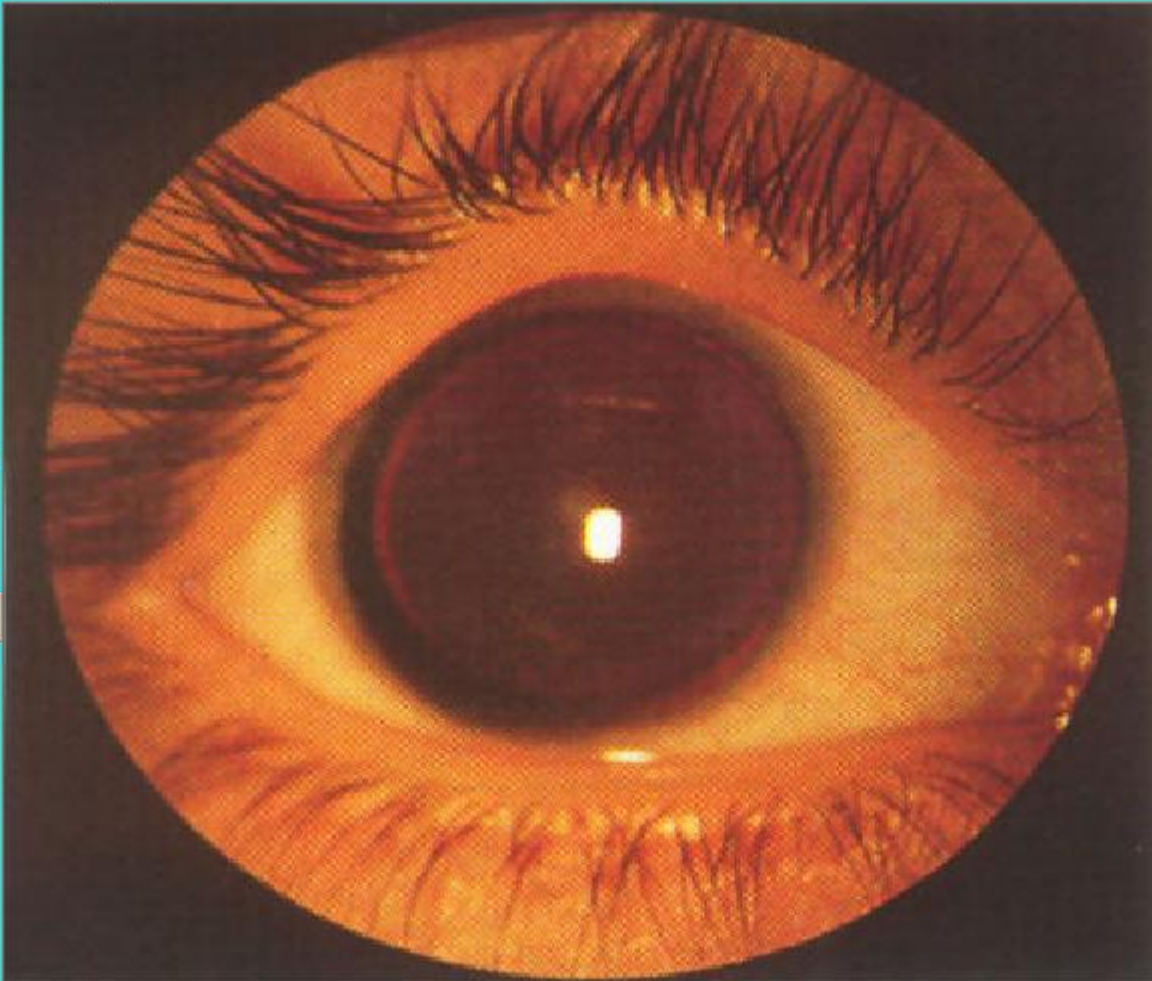


Facial + Eye + Gums Diagnosis | Eye Diagnosis+ Rx | Misc Rx | Ear + etc | Child + CPR | More Anatomy

- Brain
- Face
- Anatomy
- Brain
- Face Muscles
- Face Female
- Diagnosis

Next Dental Pic 0

Treat and Scan



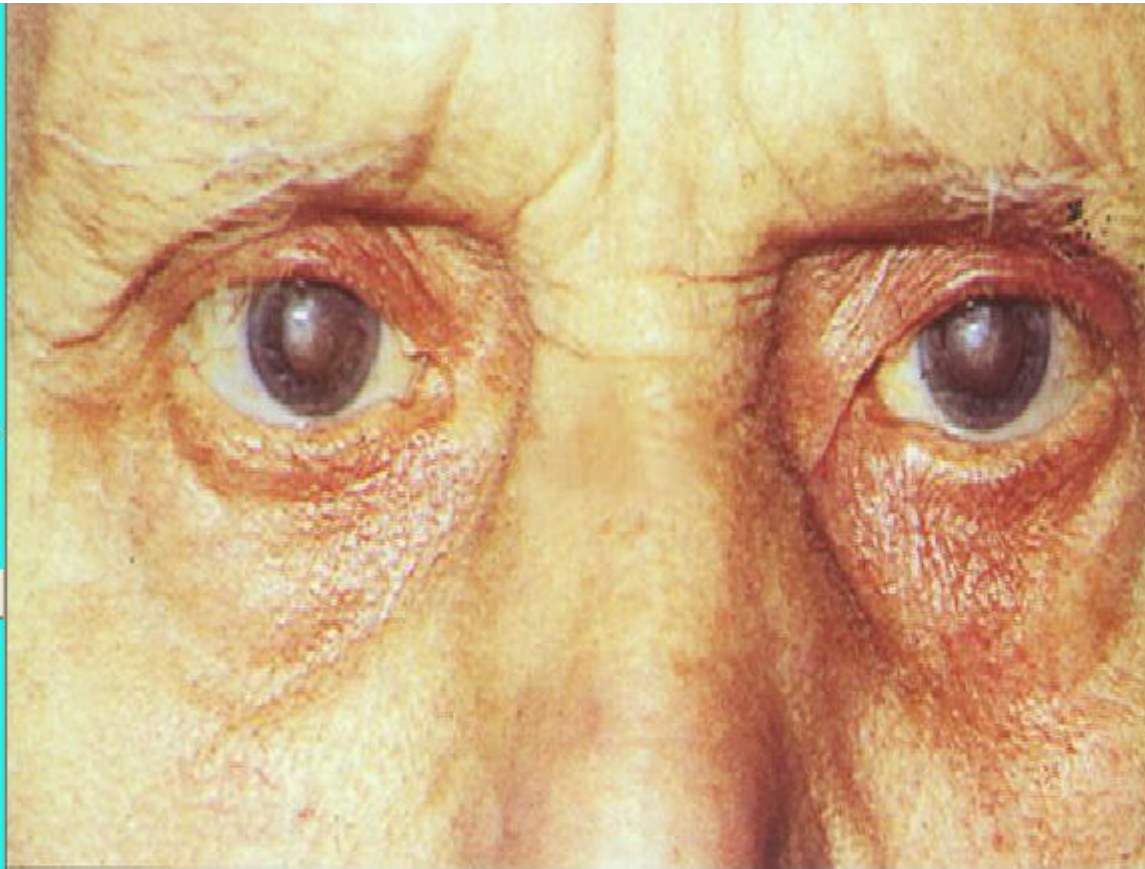AN ANIRIDIA.jpg
BASALIOMA EXULCERANS.jpg
CATARACTA INCIPIENS 2..jpg
CATARACTA MATURA 3..jpg
CATARACTA NUCLEARIS.jpg
CATARACTA SENILIS 1..jpg
CATARACTA TRAUMATICA.jpg
CERATOCONJUNCTIVITIS EPIDEMICA.jpg
CHALAZION.jpg
CHLAMYDIA INFECTIO OF A NEWLY BORN.jpg
CHLAMYDIA INFECTIO.jpg
CONGENITALIS IRISCOLOBOMA.jpg
CONJUNCTIVITIS ACUTA.jpg
CONJUNCTIVITIS CHRONICA.jpg
CONJUNCTIVITIS VERNALIS.jpg
DEGENERATIO CORNEAE NODULARIS.jpg
DEGENERATIO MACULAE LUTEAE SENILIS 1..jpg
DEGENERATIO MACULAE LUTEAE SENILIS 2..jpg
DERMOID.jpg
EPISCLERITIS.jpg
EROSIO CORNEAE RECIDIVANS.jpg
FUNGAL INFECTION.jpg
HORDEOLUM.jpg
KERATITIS METAHERPETICA.jpg
KERATITIS NEUROPARALYTICA.jpg
KERATOPLASTICL OPERATION 1..jpg
MELANOMA CONJUNCTIVAE.jpg
MEMBRANA PUPILLARIS PERSISTENS.jpg
MOLLUSCUM CONTAGIOSUM.jpg
NAEVUS IRIDIS.jpg
NAEVUS ON THE LOWER EYELID.jpg

ANIRIDIA
The total absence of the iris.

- Brain
- Face
- Anatomy
- Brain
- Face Muscles
- Face Female
- Diagnosis

Next Dental Pic 0

Treat and Scan



CATARACTA SENILIS 1.

The most usual eye disease. The cause of it is not known yet. They can cure it only with operation.

- AN ANIMATOR.jpg
- BASALIOMA EXULCERANS.jpg
- CATARACTA INCIPIENS 2.jpg
- CATARACTA MATURA 3.jpg
- CATARACTA NUCLEARIS.jpg
- CATARACTA SENILIS 1.jpg
- CATARACTA TRAUMATICA.jpg
- CERATOCONJUNCTIVITIS EPIDEMICA.jpg
- CHALAZION.jpg
- CHLAMYDIA INFECTIO OF A NEWLY BORN.jpg
- CHLAMYDIA INFECTIO.jpg
- CONGENITALIS IRISCOLOBOMA.jpg
- CONJUNCTIVITIS ACUTA.jpg
- CONJUNCTIVITIS CHRONICA.jpg
- CONJUNCTIVITIS VERNALIS.jpg
- DEGENERATIO CORNEAE NODULARIS.jpg
- DEGENERATIO MACULAE LUTEAE SENILIS 1.jpg
- DEGENERATIO MACULAE LUTEAE SENILIS 2.jpg
- DERMOID.jpg
- EPISCLERITIS.jpg
- EROSIO CORNEAE RECIDIVANS.jpg
- FUNGAL INFECTION.jpg
- HORDEOLUM.jpg
- KERATITIS METAHERPETICA.jpg
- KERATITIS NEUROPARALYTICA.jpg
- KERATOPLASTICL OPERATION 1.jpg
- MELANOMA CONJUNCTIVAE.jpg
- MEMBRANA PUPILLARIS PERSISTENS.jpg
- MOLLUSCUM CONTAGIOSUM.jpg
- NAEVUS IRIDIS.jpg
- NAEVUS ON THE LOWER EYELID.jpg

100%

60%

59%

98%

100%

REPAIRED %Rectify

INFLAMATION

INFECTION

DEGENERATION

TOXIC

Stop Sounds

Scan and Treat Iridology

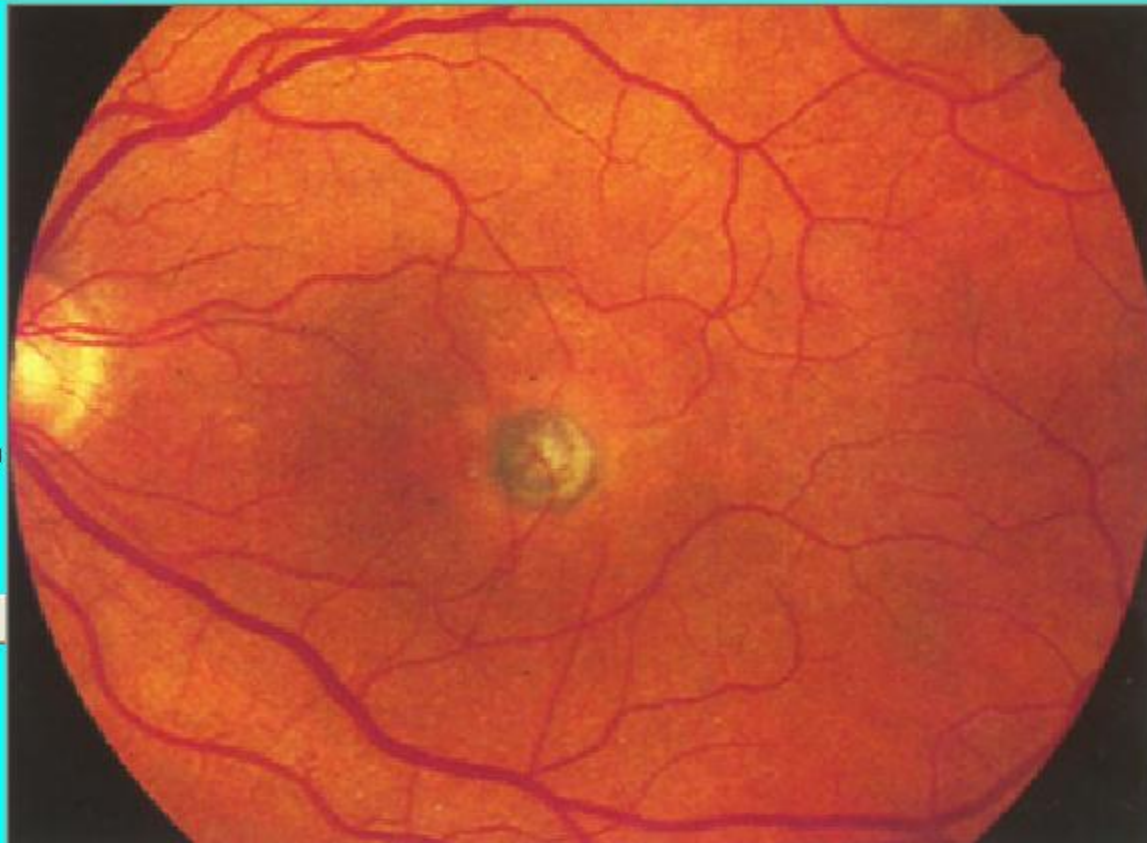Notes

Zoom

- Brain
- Face
- Anatomy
- Brain
- Face Muscles
- Face Female
- Diagnosis

Next Dental Pic 0

Treat and Scan



DEGENERATIO MACULAE LUTEAE SENILIS 1.

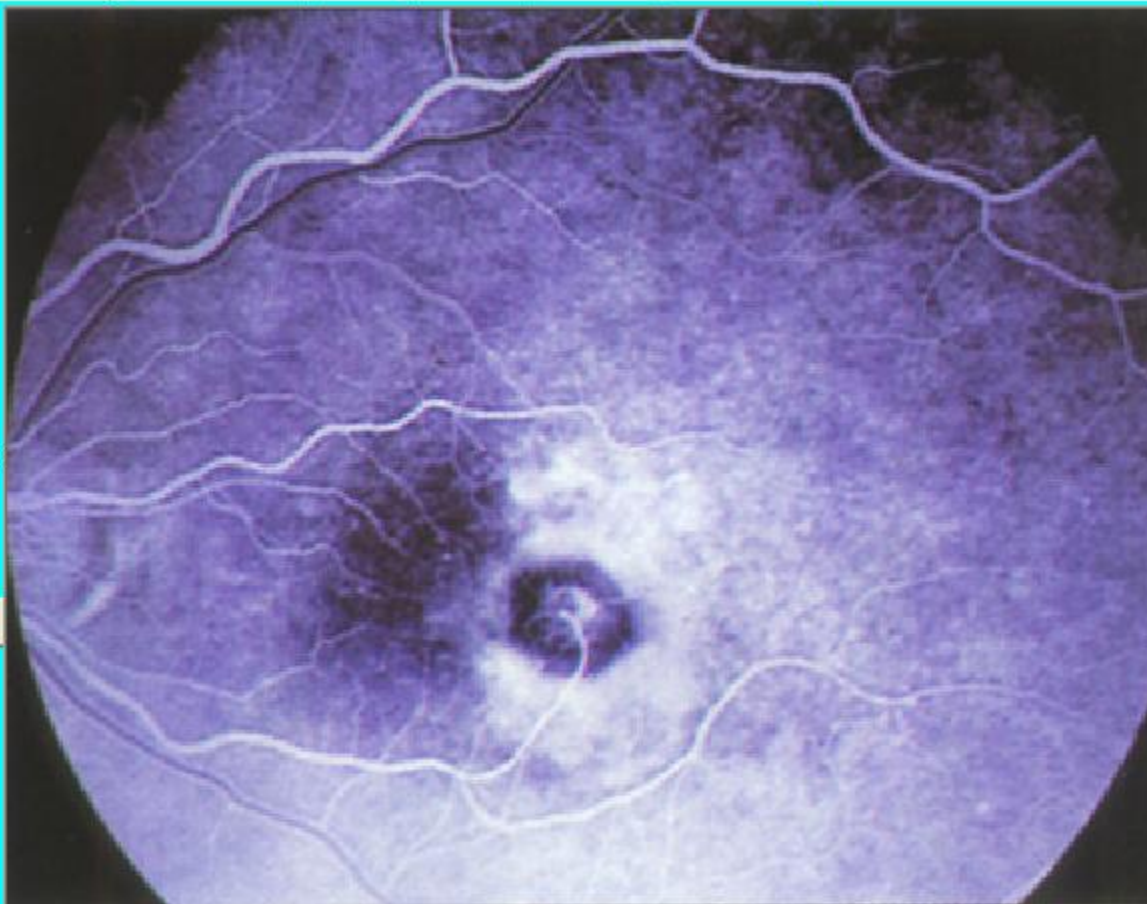
The pigmentepithelium and photoreceptor
levels are dying.

CONJUNCTIVITIS VERNALIS.jpg
DEGENERATIO CORNEAE NODULARIS.jpg
DEGENERATIO MACULAE LUTEAE SENILIS 1..jpg
DEGENERATIO MACULAE LUTEAE SENILIS 2..jpg
DERMOID.jpg
EPISCLERITIS.jpg
EROSIO CORNEAE RECIDIVANS.jpg
FUNGAL INFECTION.jpg
HORDEOLUM.jpg
KERATITIS METAHERPETICA.jpg
KERATITIS NEUROPARALYTICA.jpg
KERATOPLASTICL OPERATION 1..jpg
MELANOMA CONJUNCTIVAE.jpg
MEMBRANA PUPILLARIS PERSISTENS.jpg
MOLLUSCUM CONTAGIOSUM.jpg
NAEVUS IRIDIS.jpg
NAEVUS ON THE LOWER EYELID.jpg
PAPILLOMA CONJUNCTIVAE.jpg
PEMPHIGUS OCULARIS.jpg
PHARYNGOCONJUNCTIVALIS.jpg
PSEUDOPTERYGIUM.jpg
PTERYGIUM.jpg
SCLERITIS.jpg
STAPHYLOMA SCLERAE.jpg
SUFFUSIO CONJUNCTIVAE.jpg
TRACHOMA CONJUNCTIVITIS.jpg
ULCUS CORNEAE 1..jpg
ULCUS CORNEAE 2..jpg
ULCUS CORNEAE 3..jpg
ULCUS RODENS CORNEAE.jpg

- Brain
- Face
- Anatomy
- Brain
- Face Muscles
- Face Female
- Diagnosis

Next Dental Pic 0

Treat and Scan

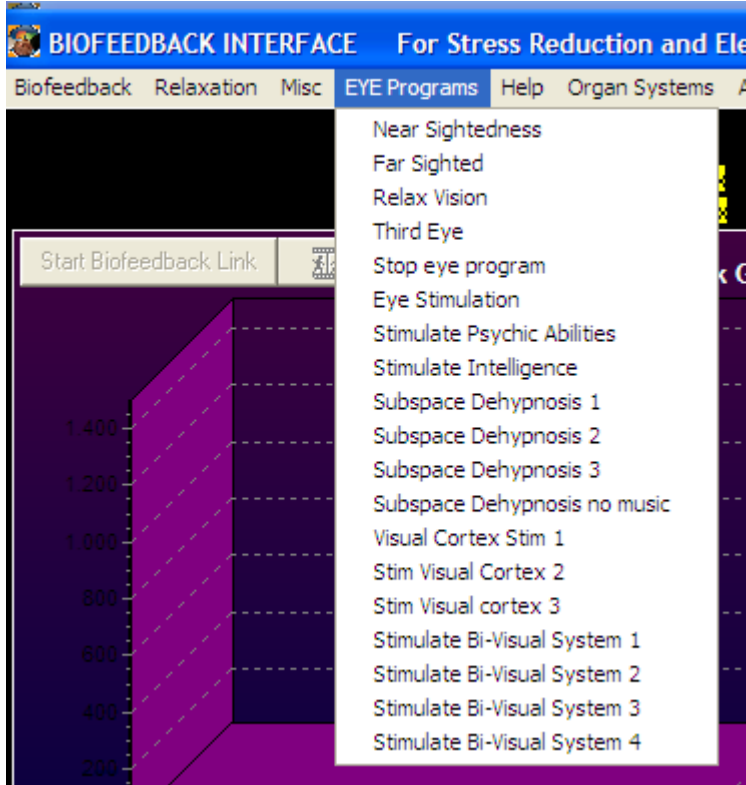


- CONJUNCTIVITIS VERNALIS.jpg
- DEGENERATIO CORNEAE NODULARIS.jpg
- DEGENERATIO MACULAE LUTEAE SENILIS 1..jpg
- DEGENERATIO MACULAE LUTEAE SENILIS 2..jpg**
- DERMOID.jpg
- EPISCLERITIS.jpg
- EROSIO CORNEAE RECIDIVANS.jpg
- FUNGAL INFECTION.jpg
- HORDEOLUM.jpg
- KERATITIS METAHERPETICA.jpg
- KERATITIS NEUROPARALYTICA.jpg
- KERATOPLASTICL OPERATION 1..jpg
- MELANOMA CONJUNCTIVAE.jpg
- MEMBRANA PUPILLARIS PERSISTENS.jpg
- MOLLUSCUM CONTAGIOSUM.jpg
- NAEVUS IRIDIS.jpg
- NAEVUS ON THE LOWER EYELID.jpg
- PAPILLOMA CONJUNCTIVAE.jpg
- PEMPHIGUS OCULARIS.jpg
- PHARYNGOCONJUNCTIVALIS.jpg
- PSEUDOPTERYGIUM.jpg
- PTERYGIUM.jpg
- SCLERITIS.jpg
- STAPHYLOMA SCLERAE.jpg
- SUFFUSIO CONJUNCTIVAE.jpg
- TRACHOMA CONJUNCTIVITIS.jpg
- ULCUS CORNEAE 1..jpg
- ULCUS CORNEAE 2..jpg
- ULCUS CORNEAE 3..jpg
- ULCUS RODENS CORNEAE.jpg

DEGENERATIO MACULAE LUTEAE SENILIS 2.

The FLAG map of the same picture.

Programy na oči: krátkozrakost', dalekozrakost', očný relax, tretie oko, očná stimulácia, stimulácia očných schopností, stimulácia očných činností, ...
stimulácia zrakovkej kôry, stimulácia videnia oboma očami



0%

Notes

Zoom

Reset

Short Cut for Rx

Close

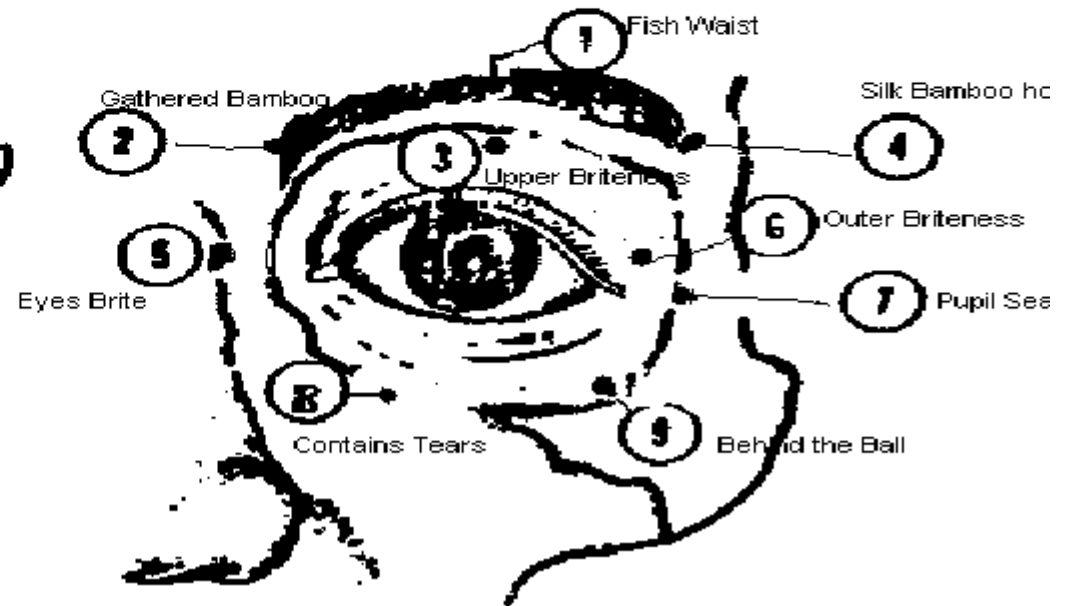
Facial + Eye + Gums Diagnosis Eye Diagnosis+ Rx Misc Rx Ear + etc Child + CPR More Anatomy

Eye points Eyestrain **Glaucoma pt Rx** Iridology Eye Anatomy Eye Muscles Sclera

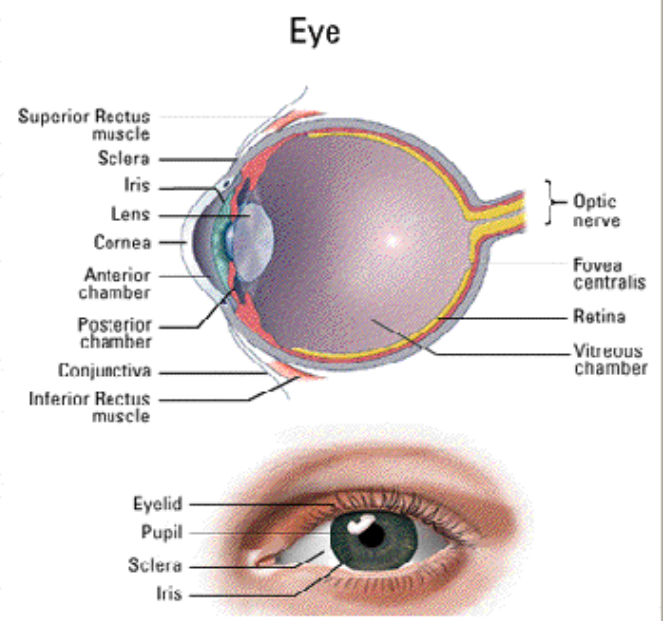
Scan and Treat Iridology

Next Eye Pic

- ① M-HN-8 (Yuyao)
- ② B-2 (Zanzhu)
- ③ N-HN-4 (Shangming)
- ④ TB-23 (Sizhukong)
- ⑤ B-1 (Jingming)
- ⑥ N-HN-8 (Waiming)
- ⑦ GB-1 (Tongzillao)
- ⑧ S-1 (Chengqi)
- ⑨ M-HN-8 (Qihou)



2595	103	Puncta Lachrymalia	EYE
2596	82	Sclerotic Coat	EYE sclera réteg a szemben
▶ 2597	79	Retina	EYE retina réteg a szemben
2598	61	Rods	EYE pálcikák a szemben
2599	111	Sinus Caroticus	
2600	102	Sinus Cavernosus	
2601	90	Sinus circularis	
2602	98	Sinus ethomoidealis	
2603	107	Sinus forntalis	
2604	110	Sinus petrosus inferior	
2605	81	Sinus lateralis	
2606	79	Sinus maxillaris	



CLICK ON AREA TO TREAT

Eye Stim FOR AREAS

Treat area
 Lower Left
 Lower Right
 Upper Left
 Upper Right
 Upper Torso
 Heart
 Head + Neck
 Low Torso

Add an Additional therapy superimposed on the treatment

Treat Facia in area
 Treat Inflammation
 Set time in minutes:

 Rectified: 37

Treat Metabolic dysfunction
 Quadrant Tension/Sarcodere Resonance/Tissue Disturbance: 66 74 56

Treat Infection
 inflammation or metabolic disorder detected

Treat Clonus or spasm in area

Treat Injury in Area
 Treat Degeneration

Treat Pain in area

Treat Fibrous tissue in the area

Use Electro Chelation Boost Therapy for circulation
 Vascular Endothelial Growth Factor, energy that stimulates growth of new blood vessel:

Pain Types—Remove Pic
 Heat Improves
 Cold Improves
 Touch Improves
 No touch Improves
 Motion Improves
 No Motion Improves
 Acid Pain
 Alkaline Pain
 ElectroMagnetic Pain
 Toxic Pain
 Referred Pain
 Geographical Pain
 Emotional or Psychic